

Enfermedades de cadenas pesadas y de cadenas livianas

Heavy and Light Chain Deposition Disease

Joseph Mikhael

*Jefe de Sección del Servicio de Hematología y Hemoterapia
Hospital Universitario La Paz, Madrid*

*Fecha de recepción: 27/08/2014
Fecha de aprobación: 15/09/2014*



CONFERENCIA

HEMATOLOGÍA
Número Extraordinario: 12-14
Octubre 2014

Palabras clave: enfermedad de cadenas pesadas,
cadenas livianas,
depósito.

Keywords: heavy chain,
light chain,
deposition disease.

The spectrum of plasma cell dyscrasias is very large – from indolent monoclonal gammopathies that will never require intervention, to rapidly progressive plasma cell leukemias with dismal prognosis. By far the most common plasma cell dyscrasia is multiple myeloma – although accounting for only 1-2% of all malignancies, there has been great interest of late in this disease due to the emergence of novel agents, the use of autologous stem cell transplant and dramatic improvement in survival. The second most common plasma cell disorder is AL amyloidosis. Although much less common, this disease has also undergone a mini revolution of late, with developments in therapy, primarily due to the use of bortezomib based strategies and concomitant improvement in survival.

However, there remain several other plasma cell dyscrasias that pose a challenge for the clinician.

These include heavy and light chain deposition disease, POEMS syndrome, Schnitzler's syndrome, among others. This lecture will focus on the heavy and light chain deposition diseases, outlining the importance of accurate diagnosis, features of its pathology, and an approach to therapy.

Heavy chain deposition disease (HCDD) and light chain deposition disease (LCDD) are monoclonal gammopathies that are characterized by nonamyloid deposition of immunoglobulin heavy or light (or both) chains in organs. The most common site of deposition is the kidney, and clinically this disease classically presents with renal dysfunction. It is generally detected on kidney biopsy when renal insufficiency with proteinuria is being investigated. LCDD is much more common, accounting for over 80% of these disease, with the remaining being HCDD or combined light and heavy deposition

disease.

The disease is in the class of “monoclonal immunoglobulin deposition diseases” in the WHO classification of malignancies, and was first described in 1976 by Randall et al. It is the result of a single clone of plasma cells in the marrow that overproduce either kappa or lambda heavy or light chains. These immunoglobulins can usually be detected in the serum, but not universally. As with myeloma, it is more common in men, but the average age of diagnosis is nearly a decade younger than that of myeloma.

Although the deposition of immunoglobulin can occur in nearly any organ, it is most commonly discovered in the kidney. Patients generally present with renal insufficiency, proteinuria, and possibly hypertension. Interestingly the degree of immunoglobulin secretion does not always correlate with the degree of organ damage. This is much like AL amyloidosis – the actual quantitative level of light chains is not prognostic, but the affinity of the heavy or light chains for the organs is most important. We do not have a measure of that affinity, but it may explain the variability of levels and degree of renal pathology.

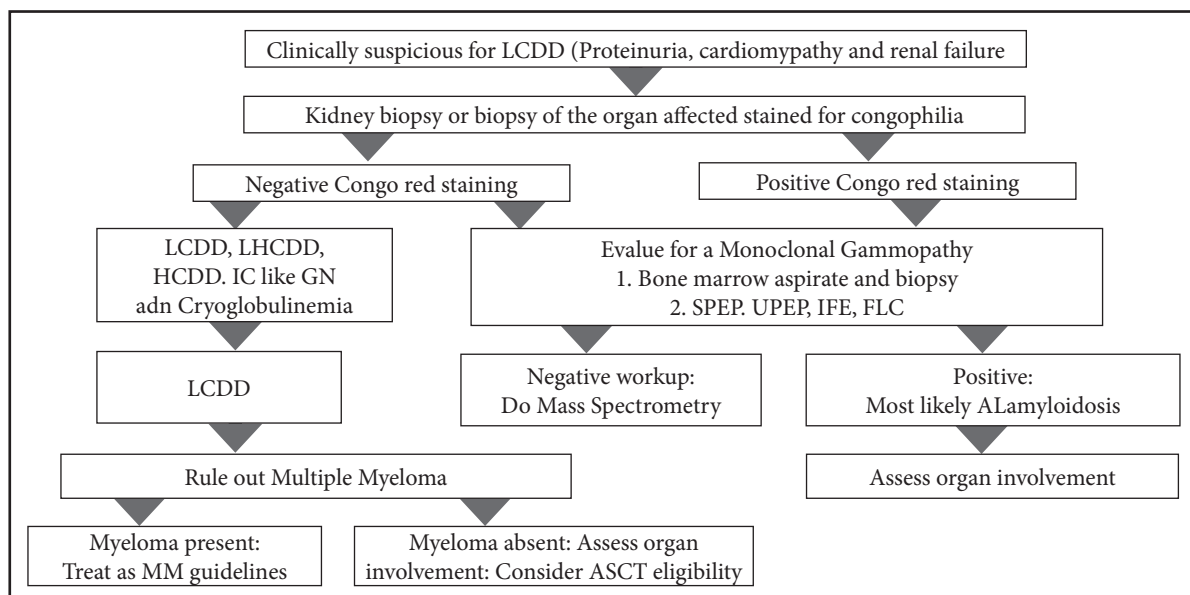
Renal pathology usually demonstrates nodular sclerosing glomerulopathy by light microscopy, diffuse linear staining of glomerular basement membranes (GBM) and tubular membranes (TBM) for a single light chain by immunofluorescence and

nonfibrillar electron dense deposits in GBMs and TBMs detected by electron microscopy. There is a very strong kappa predominance, accounting for over 90% of the deposits.

Extrarenal involvement is not common and not often clinically apparent. However, it can occur in nearly any organ; the most likely to be involved include the liver, heart, lung, and nerves.

The association of HCDD and LCDD with other B cell malignancies is complex and not well understood. Due to overlapping diagnostic criteria it may be difficult to truly distinguish from myeloma; indeed, approximately ½ of cases of LCDD are associated with myeloma, either at diagnosis, or as “extramedullary” disease later in the disease course.

The diagnostic approach to LCDD is summarized in the figure (used by permission Jimenez-Zepeda, Int J of Lab Hem 2012). As with all plasma cell disorders, patients require evaluation with CBC, biochemical profile, serum and urine protein electrophoresis, 24 hr urine collection, quantitative immunoglobulins and free light chain evaluation. If available, heavyite may be of benefit also. The critical role of immunoglobulin light chains cannot be overemphasized, as they generally not only provide diagnostic insight, but also provide the means of monitoring disease response. Kidney biopsy is also mandatory to ensure classic deposition is identified and amyloidosis excluded.



The median survival for LCDD has been reported to be approximately 4 years, although this is likely improving with better therapies. Limited data is available on therapy and so the approaches used in myeloma or AL amyloidosis are generally employed in LCDD and HCDD. Much like AL amyloidosis, the plasma cell burden in the marrow tends not to be high (rarely more than 10%); if however, there is clearly coexisting myeloma, then standard myeloma treatments should be employed.

Historically the most commonly used regimen for HCDD or LCDD was melphalan and prednisone – this was effective, especially if introduced before end stage renal disease developed. In eligible patients, autologous stem cell transplant should be considered, as outcomes for both hematological and organ response have been reported to be greater than 60%.

More recently the novel agents have been introduced with improved outcomes. Reports of the use of

thalidomide, bortezomib and lenalidomide have all been published and will be discussed in greater detail. The most promising outcomes have been with bortezomib, due to its rapid response and lack of renal clearance. These approaches are also highly favored in patients ineligible for stem cell transplant and may indeed obviate the need of transplant in some.

Renal transplantation has also been reported, but re-emergence of deposits have been reported in the transplanted kidney. It is generally reserved, therefore, for patients in whom control of the plasma cell clone is definitive and whose course may be more indolent.

It is apparent that more data is needed to guide the care of patients with HCDD and LCDD. With the introduction of more novel agents, including carfilzomib, pomalidomide and monoclonal antibodies, it is expected that outcomes for these patients will continue to improve.